

AN APPROACH TO NYSTAGMUS

Steven L. Galetta, MD
NYU Langone Medical Center
New York, NY

INTRODUCTION:

One way to organize nystagmus is to distinguish those patients with jerk properties from those with pendular waveforms.

I. Jerk Nystagmus

1. Pathologic gaze evoked
 - A. cerebellar vs. peripheral vestibular
 - B. Brun's nystagmus
 - C. rebound
 - D. dissociated (INO)
2. Periodic
3. Downbeat
4. Upbeat

II. Pendular Nystagmus

1. Oculopalatal
2. SeeSaw
3. Oculomasticatory myorhythmia
4. Monocular visual loss
5. Spasmus nutans

III. Mixed Waveform

1. Congenital

1. Physiologic nystagmus: Most normal individuals will have nystagmus that fatigues with prolonged lateral gaze of about 30°. In extreme lateral gaze of 40°, some normal patients will develop sustained physiologic nystagmus.^{1,2} However, the amplitude of this nystagmus is less than 3° and it is symmetric in right and left gaze. Occasionally, physiologic nystagmus may be asymmetric between the two eyes. Often, the nystagmus is more prominent in the abducting eye. In this situation, it may be confused with the dissociated nystagmus that accompanies internuclear ophthalmoparesis.

2. Gaze evoked nystagmus is pathologic when there is: 1) an amplitude of greater than 4°. 2) asymmetry in right and left gaze. 3) exponential slow phase velocity when the gaze angle is less than 40°. ¹ Unilateral gaze evoked nystagmus may indicate ipsilateral cerebellar or brainstem disease. Lesions involving the medial vestibular nucleus, nucleus prepositus hypoglossi and flocculus have been implicated in gaze evoked nystagmus of CNS origin. Gaze evoked nystagmus may also be observed contralateral to peripheral vestibular pathway damage. Some features may help distinguish central causes of nystagmus from peripheral vestibular disease

- **Peripheral nystagmus is unidirectional and jerk**
- **A Pure torsional or a vertical component to the nystagmus suggests a central nervous system process**
- **If the nystagmus is direction changing, a CNS process is suggested. For instance right beating in right gaze and left beating in left gaze.**
- **After head shaking for 15 seconds if a horizontal nystagmus appears, peripheral nystagmus is suggested. The nystagmus usually beats towards the good ear.**
- **Head thrust-peripheral vestibular lesions show a catch-up saccade**

When present in both horizontal and upgaze, gaze evoked nystagmus usually signifies a toxic metabolic process. When gaze evoked nystagmus is asymmetric or present in only one direction, a structural lesion is suggested (i.e. stroke, demyelinating disease). Gaze evoked upbeat nystagmus commonly accompanies bilateral internuclear ophthalmoparesis.

A special form of gaze evoked nystagmus known as Brun's nystagmus may be seen with large cerebellopontine angle lesions. Pathologic gaze evoked nystagmus is typically observed when the patient gazes toward the side of the lesion and is probably produced by impaired connections from the cerebellar flocculus. Gaze away from the lesion is associated with the appearance of a high frequency, low amplitude nystagmus reflective of vestibular dysfunction.

3. Dissociated Nystagmus: Dissociated nystagmus has been classically ascribed to the eye findings associated with an internuclear ophthalmoplegia. In this disorder, the abducting eye shows "nystagmus" with impaired adduction of the fellow eye. However, eye movements of the abducting eye may not represent a true nystagmus, but rather a series of saccades when the patient looks laterally. The abducting eye saccades may be an adaptive attempt by the brain to correct for the hypometric saccades of the weak medial rectus muscle.³ Demyelination and brainstem stroke are the most causes of internuclear ophthalmoplegia. Similar eye movements may be seen with myasthenia gravis and the Miller Fisher variant of GBS.

4. Rebound nystagmus - after the eyes have returned from eccentric gaze to the primary position the eyes beat in the opposite direction for up to 30 seconds. In rebound nystagmus, the eyes will occasionally change their fast phase direction with prolonged eccentric gaze. This finding usually indicates cerebellar disease.¹

5. Periodic alternating nystagmus (PAN) is a rare nystagmus that may be acquired or congenital. It is a nystagmus that changes directions every 90 seconds with a rest period of 5 to 10 seconds. The hallmark of PAN is a shifting null (quiet) point. PAN may be seen with downbeat nystagmus and usually indicates a lesion of the cervico-medullary junction or cerebellar nodulus.⁴ One report documents PAN in a patient with an isolated infarction of the cerebellar nodulus.⁵ PAN may also occur in degenerative processes involving the cerebellum such as olivopontine cerebellar atrophy. Experimentally, removal of the nodulus and uvula produce periodic alternating nystagmus in the dark.⁶ Baclofen may ameliorate the acquired form of periodic alternating nystagmus.^{7,8} (Table 1)

6. Downbeat nystagmus typically signifies a lesion of the craniocervical junction. (Table 2) Common causes are Arnold-Chiari Type I malformations, foramen magnum mass lesions and spinocerebellar degenerations.^{4,9,10} Other important causes to consider include hypomagnesemia, thiamine deficiency, B12 deficiency along with Dilantin, Tegretol, alcohol, and Lithium toxicity.^{3,11,12} Recently, a patient with antibodies to glutamic acid decarboxylase presented with downbeat nystagmus and stiff person syndrome.¹³ Congenital downbeat nystagmus has also been reported and these patients may experience a spontaneous remission.¹⁴ In about 25% to 40% of cases, no etiology is found despite MR imaging of the cervicomedullary junction and cerebellum.¹⁵ Many of these patients with idiopathic downbeat nystagmus may have a primary degenerative process involving the cerebellum. Downbeat nystagmus is often seen best in down and lateral gaze. The mechanism for downbeat nystagmus appears to be an imbalance of the vertical semicircular canal pathways favoring the anterior canal.² Unopposed input from the anterior semicircular canal will drive the eyes slowly upward. As such, lesions involving the dorsal medulla may selectively damage crossing information from the posterior semicircular canals. Most lesions involve the cerebellar flocculus interrupting inhibitory projections upon the anterior semicircular canals. Periodic downbeat nystagmus with a cycle of 3 minutes and 30 seconds was associated with severe hypomagnesemia in one case.¹⁶ Treatment of persistent downbeat nystagmus is difficult but recent studies suggest that 3,4 diaminopyridine and 4 aminopyridine may be effective.^{17,18,19} Chlorzoxazone may be another agent to use for the symptoms of downbeat nystagmus. Clonazepam, gabapentin and Baclofen may also be tried.^{20,21,22} A small number of patients respond to prism therapy either to induce convergence or to deflect the perceived image upward.^{2,23} The latter technique keeps the eyes out of downgaze where downbeat nystagmus is usually maximal.

7. Upbeat nystagmus in the primary position does not have the localizing value of downbeat nystagmus. (Table 2) Lesions producing upbeat nystagmus presumably damage connections of the anterior semicircular canal crossing in the ventral medulla and traveling through the brachium conjunctivum.²⁴⁻²⁶ However, upbeat nystagmus may also occur with lesions of the midbrain and cerebellum. Upbeat nystagmus that increases in downgaze usually signifies a medullary lesion. A clinicopathologic study of a patient with upbeat nystagmus worse

in downgaze revealed a lesion of the intercalatus nuclei in the medulla.²⁷ Other patients with upbeat nystagmus have had similar lesion in the dorsal paramedian medullary region.²⁸ Multiple sclerosis, infarction, cerebellar degeneration, and tumors are among the most common causes of upbeat nystagmus.² Treatment of upbeat nystagmus is similar to downbeat nystagmus and can include 4 aminopyridine, 3,4 diaminopyridine and clonazepam.^{29, 30}

8. Pendular nystagmus occurs when the eyes move back and forth with equal velocity. There are only slow phases without a jerk or fast component. This type of nystagmus may be horizontal, vertical or a combination of both. Oblique, elliptical or circular pendular nystagmus may occur depending on how the vertical phase of nystagmus relates to the horizontal phase. Pendular nystagmus may also be dissociated and this tends to occur when one eye has impaired visual function. Acquired pendular nystagmus is most often caused by multiple sclerosis and brainstem infarctions. In children, it may occur in one eye as the result of visual loss associated with a chiasmal glioma.^{2,31} Therefore, acquired monocular pendular nystagmus in childhood should be evaluated with magnetic resonance imaging. Some adult patients with severe monocular visual loss will develop a slow (1 to 5 Hz) vertical pendular nystagmus in the affected eye. This has been called the Heimann Bielschowsky phenomenon and it usually has no clinical significance.

When pendular nystagmus occurs in combination with palatal myoclonus, the term oculopalatal tremor (myoclonus) is used. There may also be rhythmic movements of the facial muscles, larynx, and diaphragm. Oculopalatal tremor usually beats at a rate of 1-3 Hz. The entity most often follows a brainstem infarction by several months, but may begin 24 hours after the insult.³² The pathological hallmark is olivary hypertrophy. Interruption of connections between the red nucleus, inferior olive and dentate nucleus (so called Mollaret's triangle) have been implicated as the cause of oculopalatal tremor. Most cases of oculopalatal tremor involve the central tegmental tract, a pathway that connects the red nucleus and deep cerebellar nuclei to the inferior olive. Recently, it has been emphasized that the pendular nystagmus observed in MS is different from the nystagmus observed in oculopalatal tremor.⁵² The nystagmus in the oculopalatal group showed a larger mean amplitude (8 deg vs 1 deg), higher mean peak velocity (16 deg/s vs 6 deg/s), lower mean frequency (1-3 Hz vs 4-6 Hz), and a larger asymmetry and irregularity of ocular oscillations compared to the MS group. Vision related quality of life was more deteriorated in the oculopalatal tremor group than in the MS group. Gabapentin and memantine are the leading choices to treat pendular nystagmus. Valproic acid and Clonazepam may also lessen this nystagmus.³³

A rare pendular slow (1 Hz) convergence nystagmus may occur in association with slow rhythmic movements of the jaw and other muscles. This has been called oculomasticatory myorhythmia and it strongly suggests the diagnosis of Whipple's disease.³⁴ This eye movement is usually associated with supranuclear ophthalmoparesis. The major drugs to treat pendular nystagmus include gabapentin, memantine, anticholinergics, Baclofen, Valproic acid, Clonazepam, and Carbamazepine.³⁰ In a randomized control trial of three muscarinic antagonists, scopolamine was found to be superior to benztropine and glycopyrrolate.³⁵ Both visual acuity and oscillopsia improved significantly with scopolamine.

Prisms and other devices such as a positive spectacle lens combined with a negative contact lens may also be used.^{2,23,36-38,39} Invasive procedures may include muscle surgery and botulinum toxin injections. Eye muscle surgery attempts to move the eyes from their eccentric null point to the primary position. This will shift the null point to a cosmetically better position. Injecting botulinum toxin into the extraocular muscles may help a small number of patients but it is limited by the ptosis and double vision it produces. Typically, patients will have to patch the worse-seeing eye for comfort.^{40,41} The need for repetitive injections is another detracting factor.

9. Convergence retraction nystagmus is a sign of pretectal dysfunction. It is not a true nystagmus because there is no slow phase, just opposing adducting saccades. Retraction results from cofiring of horizontally and vertically acting extraocular muscles. Convergence retraction saccades are elicited by having the patient look upward or by running an OKN tape downward.

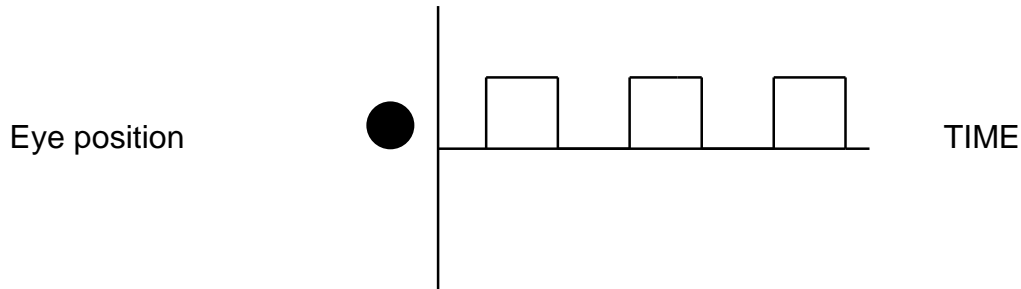
10. See Saw Nystagmus - this unusual nystagmus is characterized by the simultaneous pendular elevation and intorsion of one eye with the depression and extorsion of the other eye.^{42,43} To complete the seesaw cycle, the eye that was depressed and extorted will elevate and intort and the eye that was elevated will fall and extort. Patients with congenital seesaw nystagmus may show no torsional component and the elevating eye may extort while the falling eye intorts. Some patients will display half of a seesaw cycle with a corrective quick phase. This has been called hemi or jerk seesaw nystagmus.⁴⁴ It typically occurs from a unilateral meso-diencephalic lesion involving the interstitial nucleus of Cajal.

Pendular seesaw nystagmus is usually caused by a parasellar mass lesion (e.g. pituitary tumor, craniopharyngioma). It may be abolished by removal of the offending parasellar mass lesion. Baclofen and Clonazepam may help lessen the nystagmus. ^{20,23}

11. **Saccadic intrusions**

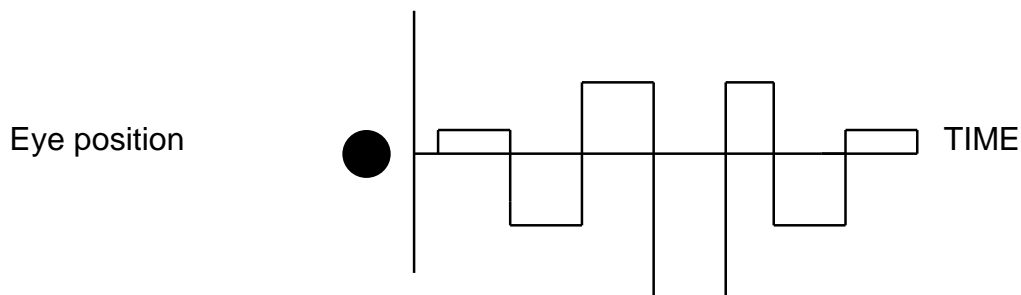
A. **Square wave jerks** are horizontal back-to-back saccades that interrupt fixation. ¹ There is an intersaccadic interval of 200ms to help distinguish this saccadic disorder from ocular flutter. If the amplitude is greater than 5°, the term macrosquare wave jerk is used. Square wave jerks may be seen in normal individuals but more than 9 per minute is considered abnormal. Common causes of square wave jerks include cerebellar disease, Parkinson's disease and progressive supranuclear palsy.

Square wave jerks



B. **Macrosaccadic oscillations** are horizontal saccades that occur across the intended fixation point in a crescendo-decrescendo pattern. Again, this is a cerebellar eye sign. ¹

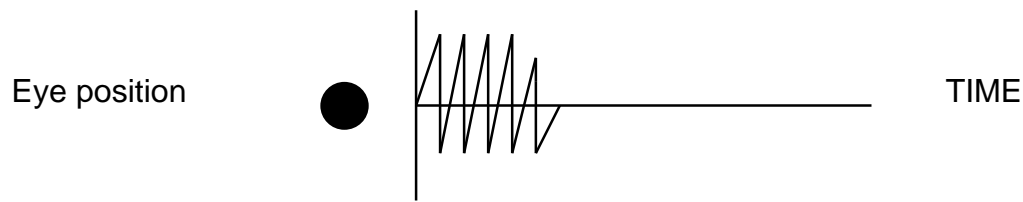
Macrosaccadic oscillations



C. **Opsoclonus** describes the dramatic occurrence of involuntary conjugate multidirectional saccades that occur without an intersaccadic interval. In children, it may occur in association with myoclonus and ataxia. This condition often responds to ACTH or corticosteroids. It is essential to exclude occult neuroblastoma in a child with opsoclonus, and such patients require imaging of the thorax and abdomen. In adults, opsoclonus may be post-infectious, drug-induced (amitriptyline, lithium, phenytoin, cocaine) or occur as the remote effect of cancer (The Anti-Ri syndrome) or encephalitis including Lyme disease and West Nile infection. ⁴⁵⁻⁴⁸ Opsoclonus may occur from cerebellar or brainstem disease. The exact etiology of opsoclonus remains uncertain, but impaired inhibition by the omnipause neurons or instability of the burst neurons have been proposed mechanisms. One leading hypothesis is that opsoclonus results from disinhibition of the cerebellar fastigial nucleus. ⁴⁵

D. Ocular flutter refers to back-to-back horizontal saccades without an intersaccadic interval. There is no vertical component. Ocular flutter has the same clinical implication as opsoclonus. Saccadic intrusions may be treated with Clonazepam and Phenobarbital.

Ocular flutter



12. Superior oblique myokymia or microtremor is a monocular oscillation produced by spontaneous firing of one superior oblique muscle. Patients often complain of monocular oscillopsia. The diagnosis is made by asking the patient to look into the field of action of the superior oblique muscle while you observe the eye with a slit lamp or the fundus with an ophthalmoscope.⁴⁹ This condition is usually idiopathic, but neuroimaging should be performed to exclude a midbrain lesion or to detect evidence of microvascular compression of the fourth nerve.⁵⁰ This disorder may spontaneously remit but Gabapentin, Carbamazepine or Propanolol may be tried in resistant cases. If symptoms persist and are disabling, one could consider tenotomy of the superior oblique muscle, in combination with recession of the inferior oblique muscle. Recently, microvascular decompression has been performed in refractory cases.⁵¹

REFERENCES

1. Dell'Osso LF, Daroff RB, Troost TB. Nystagmus and saccadic intrusions and oscillations. In: Glaser JS, ed. Neuro-Ophthalmology. Philadelphia: Lippincott, 1990:325-359.
2. Leigh RJ, Zee DS. The Neurology of Eye Movements. 4th ed. New York : Oxford University Press , 2006:475-598
3. Zee DS, Hain TC, Carl JR: Abduction nystagmus in internuclear ophthalmoplegia. Ann Neurol 21(4):383, 1987.
4. Fletcher WA. Nystagmus: an overview. In: Sharpe JA, H.O. B, ed. The vestibulo-ocular reflex and vertigo. New York: Raven Press, 1993:195-215.
5. Jeong HS, Oh JY Kim J et al: Periodic alternating nystagmus in isolated nodular infarction. Neurology 68: 956-957, 2007
6. Waespe W, Cohen B, Raphen T. Dynamic modification of the vestibulo-ocular reflex by the nodulus and uvula. Science 1985;228:199-202.
7. Halmagyi GM, Rudge P, Gresty MA, et al. Treatment of periodic alternating nystagmus. Ann Neurol 1980;8:609-611.
8. Larmande P. Baclofen as a treatment for nystagmus. Ann Neurol 1982;11:213.
9. Halmagyi GM, Rudge P, Gesty MA, et al. Downbeating nystagmus. A review of sixty two cases. Arch Neurol 1983;40:777-784.
10. Buttner U, Helmchen CH, Buttner-Ennever JA. The localizing value of nystagmus in brainstem disorders. Neuro-ophthalmology 1995;15:283-290.
11. Chrousos GA, Cowdry R, Schuelin M, et al. Two cases of downbeat nystagmus and oscillopsia associated with carbamazepine. Am J Ophthalmol 1987;103:221-224.
12. Halmagyi GM, Lessel I, Curthoys IS, et al. Lithium induced downbeat nystagmus. Am J Ophthalmol 1989;107:664-670.

13. Ances B, Dalmau J, Tsai J et al. Downbeating nystagmus and muscle spasms in a patient with glutamic acid decarboxylase antibodies *Am J Ophthalmol*.2005;140:142-144.
14. Brodsky MC. Congenital downbeat nystagmus. *J Ped Ophthalmol Strab* 1996; 33: 191-193.
15. Bronstein AM, Miller DH, Rudge P, et al. Downbeating nystagmus: case report with magnetic resonance imaging and neuro-otological findings. *J Neurol Sci* 1987;81:173-184.
16. Du Pasquier R, Vingerhoets F, Safran A, et al. Periodic downbeat nystagmus. *Neurology* 1998; 51: 1478-1480.
17. Strupp M, Schuler O, Karfczyk et al: Treatment of downbeat nystagmus with 3,4 diaminopyridine: a placebo controlled study. *Neurology* 2003;61: 165-170
18. Kalla R, Glasauer S, Schautzer F et al. 4 aminopyridine improves downbeat nystagmus, smooth pursuit, and VOR gain. *Neurology* 2004; 62:1228-1229.
19. Helmchen C, Sprenger A, Rambold H et al. Effect of 3,4 diaminopyridine on the gravity dependence of ocular drift in downbeat nystagmus. *Neurology* 2004;63:752-753.)
20. Currie JN, Matsuo V. The use of Clonazepam in the treatment of nystagmus induced oscillopsia. *Ophthalmology* 1986;93:924-932.
21. Dieterich M, Straube A, Brandt T, et al. The effects of Baclofen and cholinergic drugs in upbeat and downbeat nystagmus. *J Neurol, Neurosurg, Psychiatry* 1991;54:627-632.
22. Auerbuch Heller L, Tusa RJ, Fuhry L et al. A double-blind controlled study of Gabapentin and Baclofen as treatment for acquired nystagmus. *Ann Neurol* 1997; 41: 818-825.
23. Carlow TJ. Medical treatment of nystagmus and ocular motor disorders. *Int Ophthalmol Clin* 1986;26:251-264.
24. Keane JR, Itabashi HH. Upbeat nystagmus: clinicopathologic study of two patients. *Neurology* 1987;37:491-494.
25. Nakamagoe K, Fujizuka N, Koganezawa T et al. Downbeat nystagmus associated with damage to the medial longitudinal fasciculus of the pons: A vestibular balance control mechanism via the lower brainstem paramedian tract neurons. *J Neurol Sci* 2013 328: 98–101
26. Hirose G, Kawada J, Tsukada K, et al. Primary position upbeat nystagmus. *J Neurol Sci* 1991;105:159-167.
27. Ohkoshi N, Komatsu Y, Mizusawa H, et al. Primary position upbeat nystagmus increased on downward gaze: clinicopathologic study of a patient with multiple sclerosis. *Neurology*, 1998; 50: 551-553.
28. Janssen JC, Larner AJ, Morris H et al. Upbeat nystagmus: clinical anatomical correlation. *J Neurol, Neurol Psychiatry* 1998;65:380-381.
29. Glasauer S, Kalla R, Buttner U et al. 4 aminopyridine restores visual ocular motor function in upbeat nystagmus. *J Neurol Neurosurg Psychiatry* 2005;76:451-453.
30. Straube A. In Straube A, Buttner U(eds): *Neuro-Ophthalmology*. Dev Ophthalmol. Basel, Karger, 2007, Vol40, pp175-192.
31. King RA, Nelson LB, Wagner RS. Spasmus nutans. A benign clinical entity? *Arch Ophthalmol* 1986;104:1501-1504.

32. Kim JS, Moon SY, Choi KD et al. Patterns of ocular oscillation in oculopalatal tremor: Imaging Correlations. *Neurology* 2007; 68:1128-1135
33. Lefkowitz D, Harpold G. Treatment of ocular myoclonus with Valproic acid. *Ann Neurol* 1985;17:103-104.
34. Schwartz MA, Selhorst JB, Ochs AL, et al. Oculomasticatory myorhythmia: a unique movement disorder occurring in Whipple's disease. *Ann Neurol* 1986;20:677-683.
35. Barton JJ, Huaman AG, Sharpe JA. Muscarinic antagonists in the treatment of acquired pendular and downbeat nystagmus: a double-blind, randomized trial of three intravenous drugs. *Ann Neurol* 1994;35:319-325.
36. Herishanu Y, Louzaun Z. Trihexyphenidyl: treatment of vertical pendular nystagmus. *Neurology* 1986;36:82-84.
37. Leigh RJ, Rushton DN, Thurston SE, et al. Effects of retinal image stabilization in acquired nystagmus due to neurologic disease. *Neurology* 1988;38:122-127.
38. Leigh RJ, Burnstine TH, Ruff RW, et al. Effect of anticholinergic agents upon acquired nystagmus: a double blind study of trihexyphenidyl and tridihexethyl chloride. *Neurology* 1991;41:1737-1741.
39. Leigh RJ, Auerbuch-Heller L, Tomsak RL et al. Treatment of abnormal eye movements that impair vision: strategies based on current concepts of Physiology and Pharmacology. *Ann Neurol* 1994; 36: 129-141.
40. Repka MX, Savino PJ, Reinecke RD. Treatment of acquired nystagmus with botulinum neurotoxin A. *Arch Ophthalmol* 1994;112:1320-1324
41. Tomsak RL, Remler BF, Auerbach-Heller L. Unsatisfactory treatment of acquired nystagmus with retrobulbar injection of botulinum toxin. *Am J Ophthalmol* 1995; 119:489-496
42. Daroff RB. See-saw nystagmus. *Neurology* 1965;15:874-877.
43. Nakada T, Kwee IL. See-saw nystagmus: role of visual vestibular interaction in its pathogenesis. *J Clin Neuro-ophthalmol* 1988;8:171-177.
44. Halmagyi GM, Aw ST, Dehaene I. Jerk-waveform see-saw nystagmus due to a unilateral meso-diencephalic lesion. *Brain* 1994;117:789-803.
45. Wong A: an update on opsoclonus. *Curr Opin Neurol* 2007;20:25-31)
46. Peter L, Jung J, Tilikete C, et al. Opsoclonus-myoclonus as a manifestation of Lyme disease. *J Neurol Neurosurg Psychiatry* 2006; 77:1090–1091
47. Candler PM, Dale RC, Griffin S, et al. Poststreptococcal opsoclonus myoclonus associated with antineuroleukin antibodies. *J Neurol Neurosurg Psychiatry* 2006; 77:507–512.
48. Alshekhlee A, Sultan B, Chandar K. Opsoclonus persisting during sleep in West Nile encephalitis. *Arch Neurol* 2006; 63:1324–1326.
49. Rosenberg ML, Glaser JS. Superior oblique myokymia. *Ann Neurol* 1983;13:667-669.
50. Morrow M, Sharpe JA, Ranalli PJ. Superior oblique myokymia associated with a posterior fossa tumor: oculographic correlation with an idiopathic case. *Neurology* 1990;40:367-370.
51. Ehongo A, Abi FH, Neugroschl C, Cordonnier M: Superior oblique myokymia secondary to neurovascular compression] *Bull Soc Belge Ophtalmol* 287:79-83, 2003.

52. Tilikete C, Jasse L, Pelisson D et al. Acquired pendular nystagmus in multiple sclerosis in and oculopalatal tremor. *Neurology* 76: 670-677, 2011
53. Feil K, Jens C, Bardins S et al. Effect of chlorzoxazone in patients with downbeat nystagmus: A pilot trial *Neurology* 81: 1152–1158, 2013

TABLE 1

PHARMACOLOGIC TREATMENT OF NYSTAGMUS

PAN:	Baclofen, Phenytoin
Downbeat:	Clonazepam, 3, 4 diaminopyridine, 4 aminopyridine, Gabapentin, Chlorzoxazone
See Saw Nystagmus:	Baclofen, Clonazepam
Pendular nystagmus	Memantine, Valproic acid, Gabapentin
Opsoclonus:	Clonazepam, trihexyphenidyl, Steroids, gamma globulin , Clonazepam
Superior oblique myokymia:	Gabapentin, Tegretol, Propanolol
Oculomasticatory myorhythmia:	Ceftriaxone

TABLE 2

LOCALIZING VALUE OF NYSTAGMUS PATTERNS

<u>TYPE</u>	<u>LOCALIZATION</u>
1. Downbeat	Cervicomedullary or cerebellar flocculus
2. Periodic alternating	Cervicomedullary or cerebellar nodulus
3. Upbeat	Cerebellum, pontomesencephalic, pontomedullary
4. Convergence retraction	Dorsal midbrain
5. SeeSaw	Parasellar, midbrain
6. Oculopalatal myoclonus	Central tegmental tract
7. Oculomasticatory myorhythmia	Whipples disease
8. Rebound	Cerebellum
9. Spasmus nutans	Exclude chiasmal glioma
10. Brun's nystagmus ¹	Cerebellopontine angle

1. Refers to ipsilateral gaze evoked nystagmus and contralateral high frequency low amplitude nystagmus of vestibular origin.